

# clinician's brief®

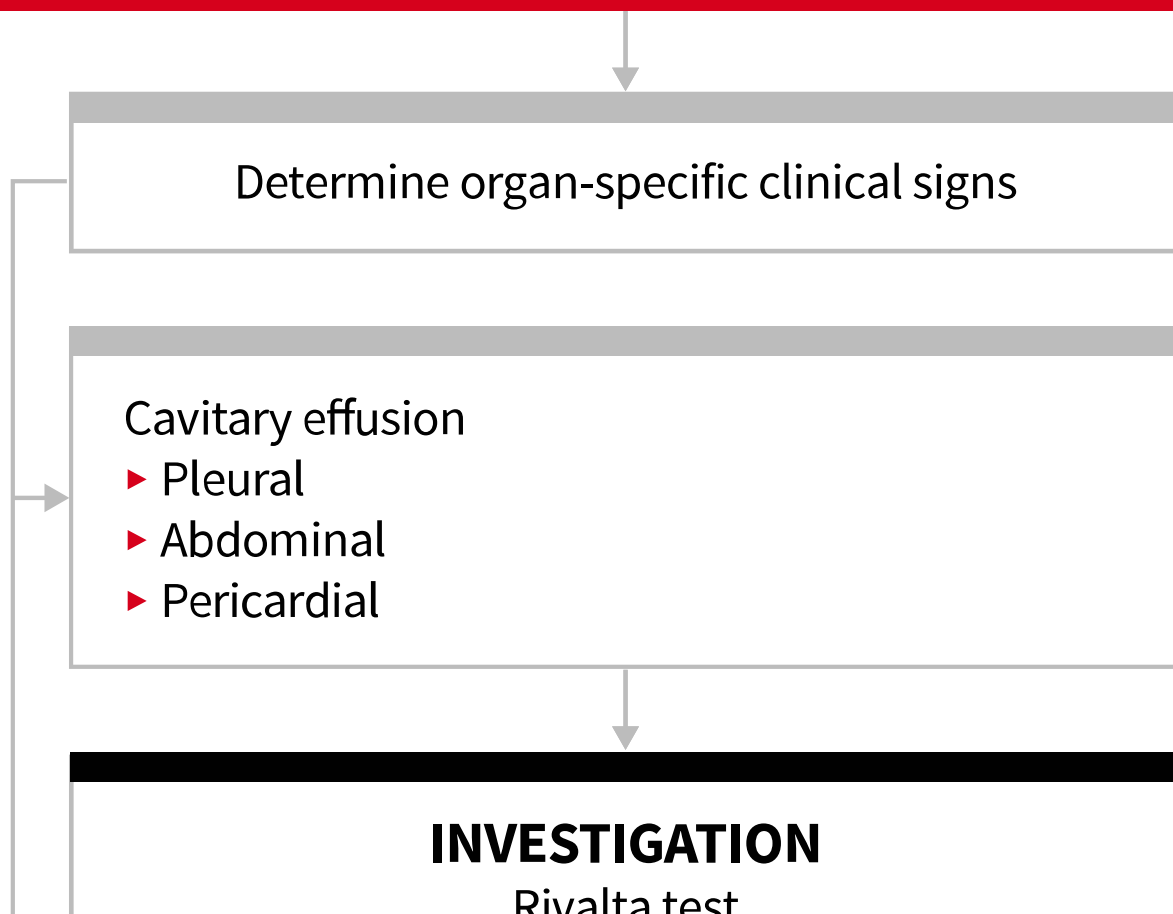
## Diagnosing Feline Infectious Peritonitis

Matthew Kornya, DVM, ABVP (Feline) Residency Trained, ACVIM (SAIM) Resident, Ontario Veterinary College, The Cat Clinic, Ontario, Canada

INFECTIOUS DISEASE | NOVEMBER/DECEMBER 2020 | PEER REVIEWED

[Print/View PDF](#)

### FIP SUSPECTED BASED ON CLINICAL SIGNS AND DIAGNOSTICS



Fluorescent antibody test

Negative

Positive

**DIAGNOSIS**  
FIP unlikely

**INVESTIGATION**  
Cytology

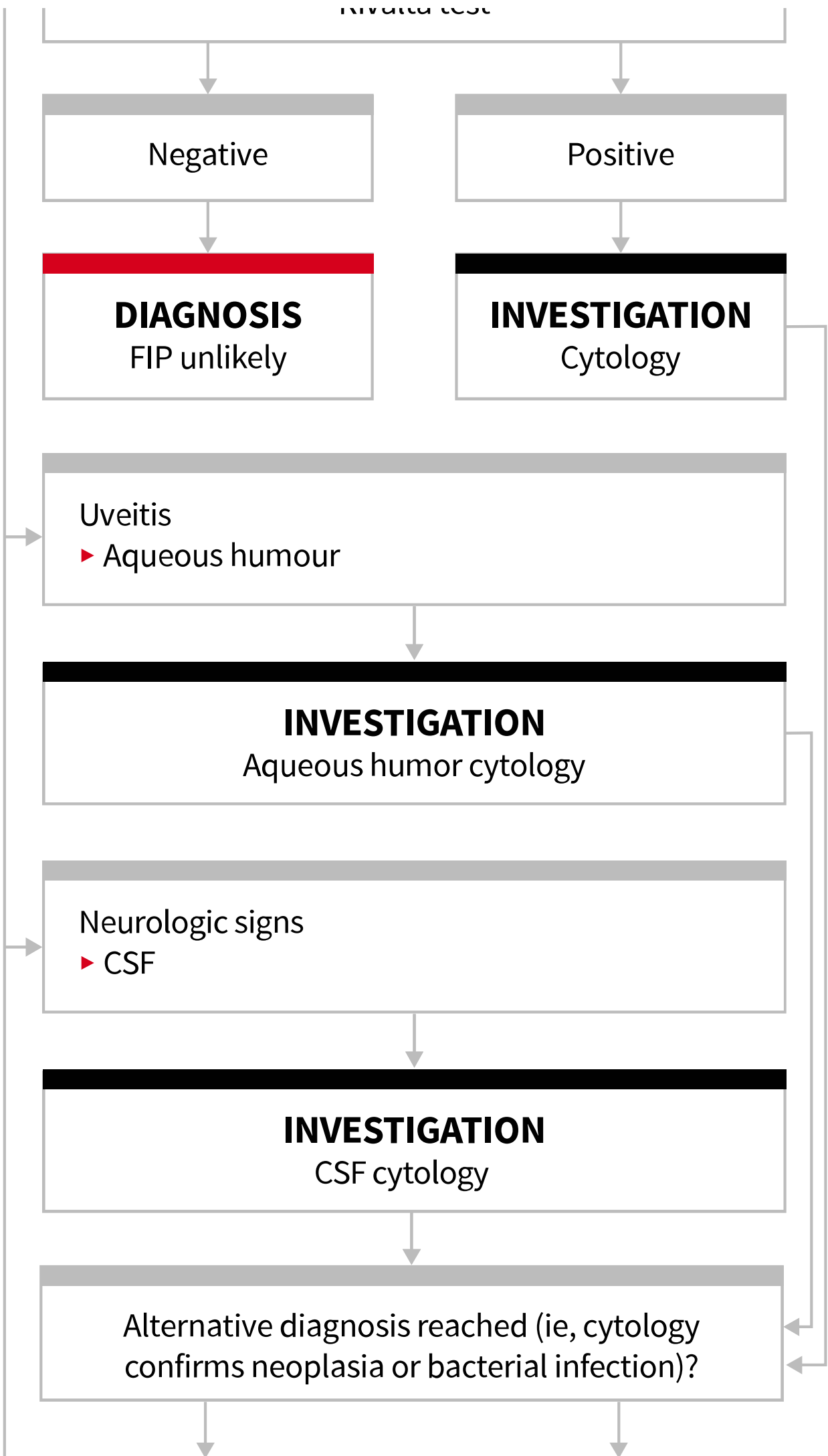
Uveitis  
▶ Aqueous humour

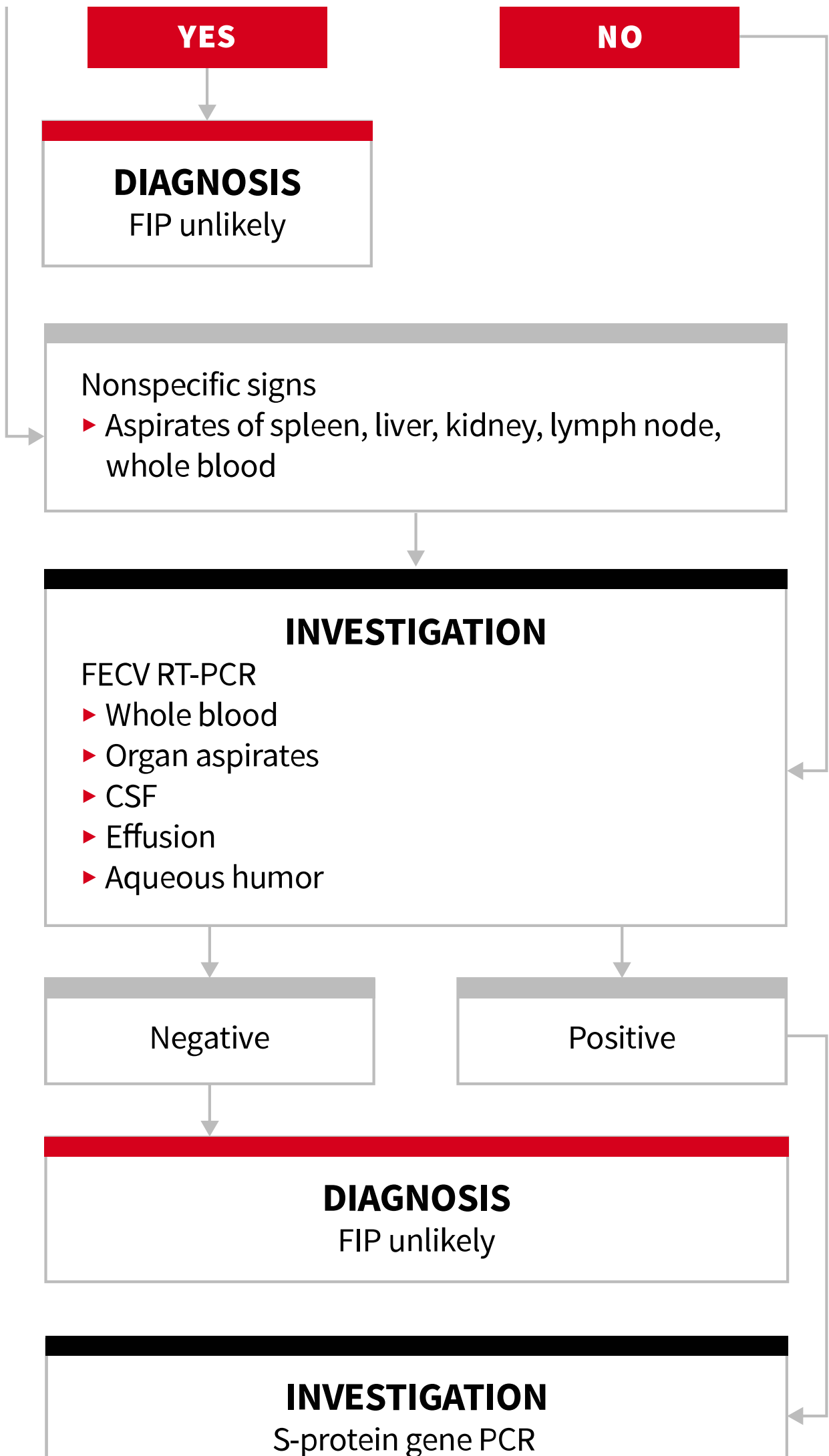
**INVESTIGATION**  
Aqueous humor cytology

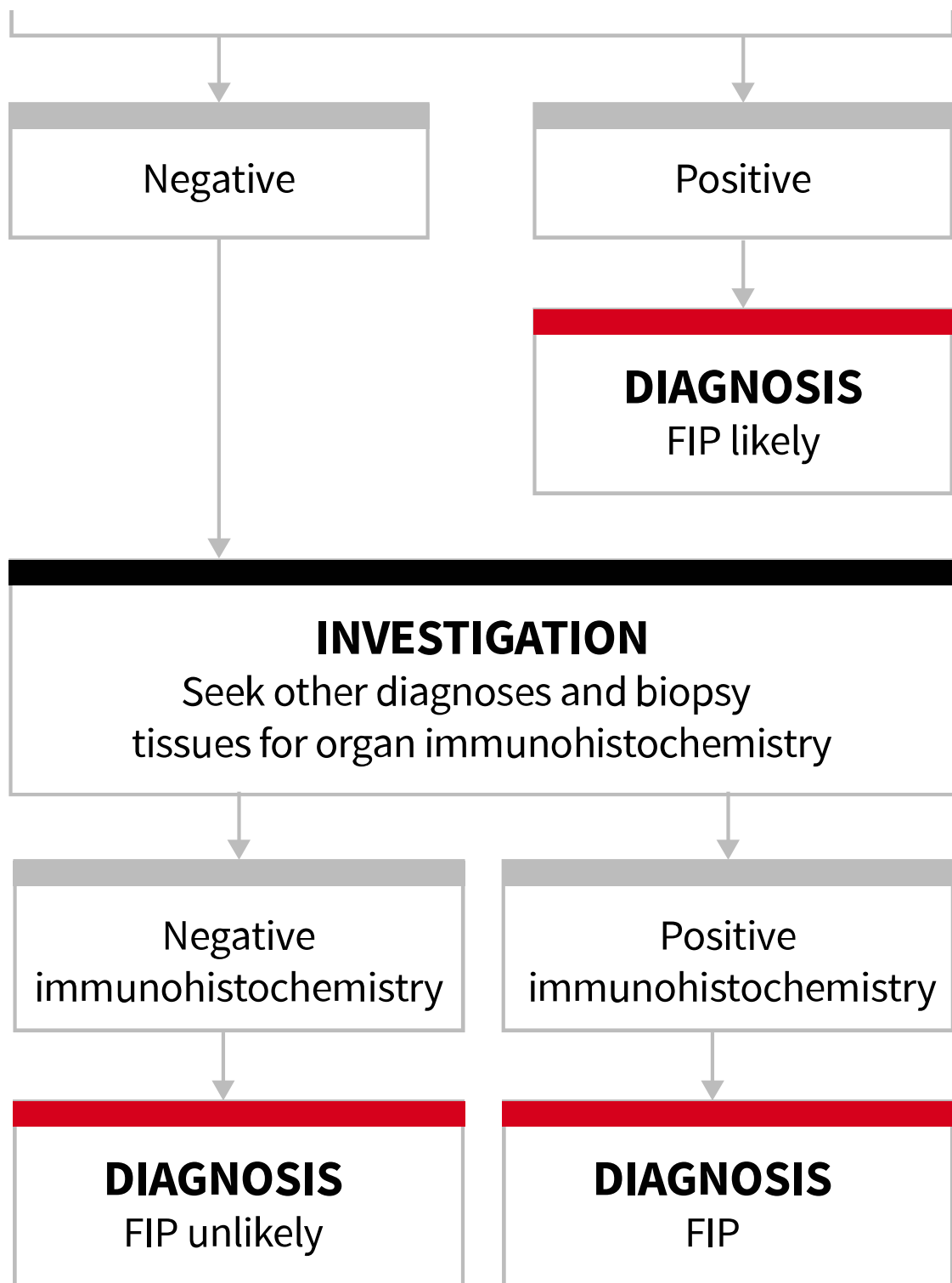
Neurologic signs  
▶ CSF

**INVESTIGATION**  
CSF cytology

Alternative diagnosis reached (ie, cytology confirms neoplasia or bacterial infection)?







FECV = feline enteric coronavirus, RT = reverse transcriptase

For global readers, a calculator to convert laboratory values, dosages, and other measurements to SI units [can be found here](#).

All *Clinician's Brief* content is reviewed for accuracy at the time of publication. Previously published content may not reflect recent developments in research and practice.

Material from *Clinician's Brief* may not be reproduced, distributed, or used in whole or in part without prior permission of Educational Concepts, LLC. [For questions or inquiries please contact us](#).

